



## **Naivasha Mobile Vet Unit**

### **Monthly report – October 2016**

#### **Introduction**

Routine clinical case interventions and research activities continued during the month. The Naivasha Mobile Unit Veterinarian visited Eburru Mountain Forest on bongo project mission.

In summary the following activities were undertaken during this month;

- i. General routine clinical case work, Eburru bongo project mission and research activities.
- ii. Attended Kenya Livestock & Wildlife Syndromic surveillance, 2 days workshop at Fairview Hotel Nairobi.
- iii. Routine security patrols in Hells Gate, Kedong ranch, Upper & Lower KARO, Manera Farm, Marula Estates and Aquilla Farm.

#### **General weather**

Nakuru and many parts South and North of Lake Naivasha during this reporting period had sporadic showers of rain. Generally mornings are cold later change to hot, sunny and windy days. The nights are cold dry and windy. Pastures are abundant in some areas and new lush grass is sprouting up.

#### **Case reports**

This is a summary of the clinical cases reported during the month.

On 04.10.2016 at Upper KARO-Opposite Malewa Primary School the team desnared a female zebra with a wire snare on the right front leg. She was darted with 6mg of etorphine plus 100mg of Azaperone using a Dan Inject dart rifle. The snare wound was cleaned with water and povidone iodine, 4500mg of Amoxicillin Trihydrate (Betamox®) and 20ml of Multivitamins were administered by Intramuscular route. Prognosis of the case is good. On the same day the team visited Lower KARO and Manera farm on a security patrol mission. All animals in this area are in sound health.

#### **Pictorial presentation of case**



On 05.10.2016 at Aquilla Farm (Lake Naivasha North) the team desnared a male zebra with a winch wire snare on left front leg. The snare wound was cleaned with water and povidone iodine. We also administered 900mg of Oxytetracyclines (Alamycin 30% LA) and 20 ml of multivitamins. Prognosis of the case is good.

**Pictorial presentation of case**



On 05.10.2016 at Sanctuary Farm (Lake Naivasha South) the team desnared a female zebra with a wire snare on the right hind leg. The snare wound was cleaned with water and povidone iodine, 4500mg of Amoxicillin Trihydrate (Betamox®) and 20ml of Multivitamins were administered by intramuscular route. Prognosis of the case is good.

**Pictorial presentation of case**



On 6<sup>th</sup> October 2016 one injured male Maasai giraffe was treated at Olerai House (Sirocco Farm). This was a repeat treatment after 2 months. He was darted using combination of 12mg Etorphine Hcl & 100mg Azaperone tartrate using a Dan Inject dart rifle. He has a chronic wound on left front leg. The chronic open wound was managed by thorough cleaning with water and diluted hydrogen peroxide, povidone iodine, plus a fly repellent (Oxytetracycline spray). Other treatments included administration of 30,000mg of Oxytetracycline (Alamycin® LA 300), 1000mg of Flunixin meglumine and 50ml of multivitamins by intramuscular route. We also trimmed the excess hoof growth to reduce lameness.

**Pictorial presentation of case**



On 6<sup>th</sup> October 2016 one injured male Rothschild's giraffe was treated at Kigio group Ranch. This was a repeat treatment after 1month. He was darted using combination of 12mg Etorphine Hcl & 100mg Azaperone tartrate using a Dan Inject dart rifle. He has a chronic wound on left front leg. The chronic open wound was managed by thorough cleaning with water and diluted hydrogen peroxide, povidone iodine, plus a fly repellent (Oxytetracycline spray). Other treatments included administration of 15,000mg of Amoxicillin Trihydrate (Betamox®), 79.2 mg of Dexamethasone and 50ml of multivitamins by intramuscular route. **Pictorial presentation of case**



On 07.10.2016 at Soysambu – Lord Delamere Estate (Airstrip area) the team desnared a female zebra with a right hind leg embedded wire snare. The traumatic injury was also maggot infested. She was darted with 6mg of etorphine plus 100mg of Azaperone using a Dan Inject dart rifle. The snare wound was cleaned with water and povidone iodine, 6000 mg of Amoxicillin Trihydrate (Betamox<sup>®</sup>), 5ml of ivermectin and 20ml of Multivitamins were administered. Prognosis of the case is good.

**Pictorial presentation of case**

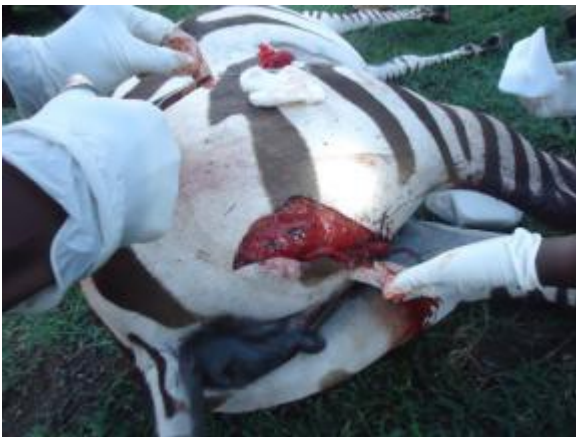

On 08.10.2016 at Soysambu, the team desnared 2 zebras with neck wire snares. The zebras were darted with 7mg of etorphine plus 100mg of Azaperone using a Dan Inject dart rifle. Prognosis of the cases is good. **Pictorial presentation of cases**




On 08.10.2016 at Sanctuary Farm (South Lake Naivasha), the team sutured one nursing female zebra which had sustained a deep sharp object cut on her gluteal muscles. She was darted with 6mg of etorphine plus 100mg of Azaperone using a Dan Inject dart rifle. The open wound was sutured using cat gut 3.0 and Nylon 3.0. Other treatments included 6,000 mg of Amoxicillin Trihydrate (Betamox®), 300mg of flunixin meglumine, and oxytetracyclines spray. The prognosis of the case is good.

**Pictorial presentation of case**



On 17<sup>th</sup> October 2016 we attended to a snared male zebra at Soysambu. The wire snare was on the left hind leg. The snare wound was cleaned with water and povidone iodine. We also administered 900mg of Oxytetracyclines (Alamycin 30% LA) and 20 ml of multivitamins. The wounds were also sprayed with oxytetracycline fly repellent spray.


## Pictorial presentation



On 20.10.2016 at Kongoni Game Valley near KWS Camp, the team treated a female zebra with lameness due to foot rot. The rotting hoof was left hind leg. The rot involved the frog part of the hoof. The wound was cleaned with water, hydrogen peroxide and povidone iodine. We also administered 6000mg of Oxytetracyclines (Alamycin 30% LA), 300mg of flunixin meglumine and 20 ml of multivitamins. Prognosis of the case is good. **Pictorial presentation of case**



On 20.10.2016 at Soysambu at Maendeleo the team treated a snared female sub adult zebra with a snare on left hind leg. The wound was cleaned with water, hydrogen peroxide and povidone iodine. We also administered 6,000mg of Oxytetracyclines (Alamycin 30% LA), 300mg of flunixin meglumine and 20 ml of multivitamins. Prognosis of the case is good. **Pictorial presentation of case**





**Ongoing research activities**

On 8<sup>th</sup>October, blood sampling of 2 donkeys at Soysambu (Research compound) was undertaken. On 24.10.2016 at Manera Farm 2 male buffaloes, blood samples were also taken. Samples taken include whole blood in EDTA and storage of the same in liquid nitrogen at -196<sup>0</sup>C and other blood samples in plain tubes for serology.

**Acknowledgements**

We profoundly appreciate steadfast financial support and resources from Animal Rights Reserved Foundation (ARR) Chief supporter and founder, Margaret and daughter Ola Zak, facilitation and managerial support by ARR General Manager, Richard Hartely and other generous partners who support wildlife conservation work in their private land. Thank you all.

Report compiled by;

Dr. Titus Kaitho  
Resident Veterinarian  
Naivasha Mobile Vet Unit